When Plasma cells mimic T-cells: Diagnostic implications of aberrant T cell marker expression in Plasmablastic Myeloma

SOHC
SWISS ONCOLOGY & HEMATOLOGY CONGRESS

Universitätsspital Basel

Abstract category: hemostasis, transfusion medicine, vascular, laboratory medicine

J. Tossounidis[1], C. Segalada[1], A. Tzankov[2], C. Berkemeier[3], D. Ditz[1], J. Dirks[1], C. Widmer[1]
[1]Department of Diagnostic Hematology, University Hospital of Basel, [2]Institute of Medical Genetics and Pathology, University Hospital of Basel,
[3]Department of Medical Immunology, University Hospital of Basel

Objective

- The diagnosis of plasma cell myeloma is usually straightforward.
- However, the morphology of neoplastic plasma cells can vary considerably, posing a diagnostic challenge.
- A 78-year-old female patient was referred to our centre with severe anaemia and osteolytic bone lesions ultimately leading to the diagnosis of plasmablastic myeloma (PBM).
- Our objective is to illustrate how comprehensive immunophenotyping, including testing for T-cell markers, can guide early suspicion and diagnostic work-up in this morphologically challenging entity.

Morphology

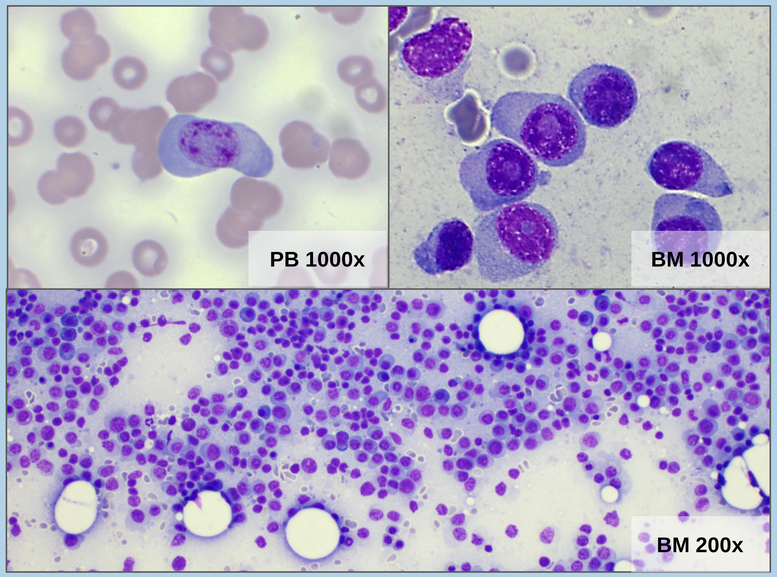

Histopathology

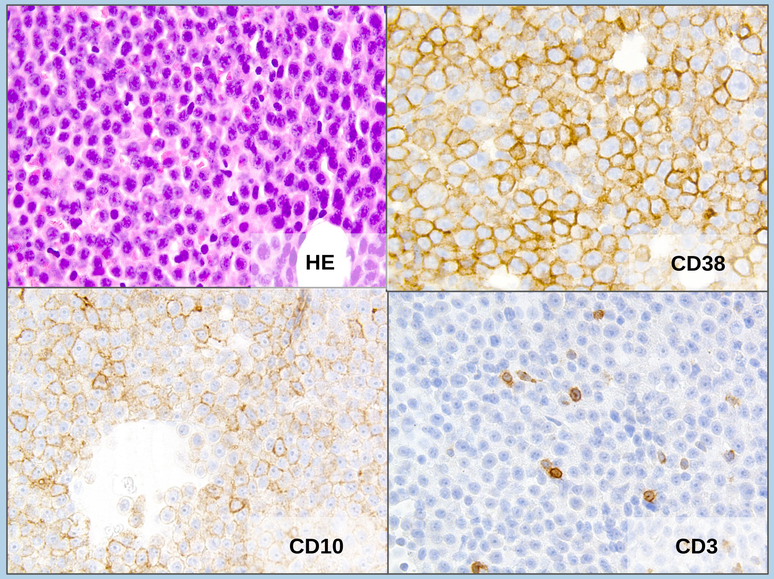

Electrophoresis & Immunofixation

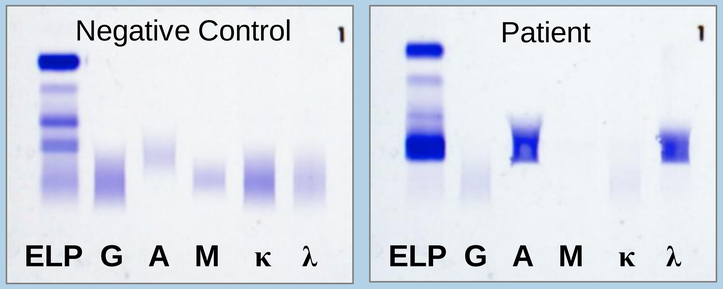

T-cell markers in plasmacytoid neoplasias

- Rare, most often CD3; other T-cell markers nearly absent

Associated with:

- plasmablastic morphology (PBM vs. PBL)
- high Ki-67 index
- extramedullary involvement
- adverse outcome / short survival

Pan et al. 2018
Solimann et al. 2021

Flowcytometric immune phenotyping

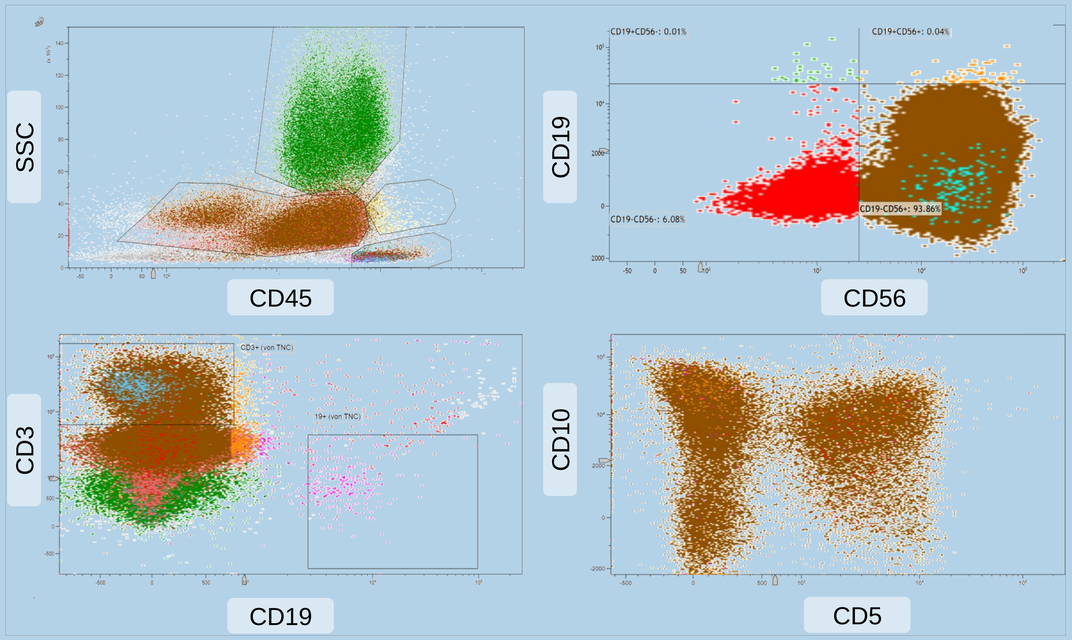

Conclusions

- Hereby, we present another rare case of aberrant T-cell marker expression (CD3 *and* CD5) in the context of plasmablastic morphology.
- Plasmablastic lymphoma (PBL) has to be ruled out as a differential diagnosis, due to its known association with T-cell marker expression.
- Our results highlight the importance of including T-cell markers in flow cytometry panels to improve diagnostic accuracy and prevent misclassification of PBM.

Presented at SOHC 2025 from 19-21 November 2025